

FORENSIC-MEDICAL ESTIMATION OF THE NON-LETHAL TRAUMATIC BRAIN INJURY OF VICTIMS, WHO WERE TREATED IN MEDICAL INSTITUTIONS

©Pletenetska A.

National medical academy of postgraduate education named after P. L. Shupyk
department of Forensic Medicine

Resume: Considering the high prevalence of traumatic brain injury in forensic practice, the article presents data from forensic examinations of victims in such cases, the main defects of doctors neurologists at diagnosis “traumatic brain injury” was described, that can help forensic experts in correct evaluation of traumatic brain injury.

Key words: forensic examination, traumatic brain injury, medico-diagnostic defects.

Materials and methods. Research materials were 1304 forensic examination of the departments of forensic examination of victims, defendants and others in one of the regional bureau of forensic medical examination Ukraine for 2008-2012. The data subjected to statistical analysis.

The aim of the research was to study the defects of medical care by doctors in cases of TBI, according to forensic examination of a bureau forensics Ukraine to prevent errors forensic experts in assessing TBI.

Results and conclusions. In the statistical analysis of examinations it was found that cases of TBI met at 37.94% of all examinations (1304 of 3437 total number). The number of examinations in cases of TBI each year increased from $25,9 \pm 2,05\%$ in 2008 to $37,38 \pm 2,05\%$ in 2012. It was found that in medical records for forensics in many cases doctors established diagnosis “TBI” incorrectly, especially in cases of clinically-mild traumatic brain injury - concussion of a brain and mild brain bruises, which amounted to 81.35% and 13.98%, respectively. During the forensic examination in all these cases the establishment of the diagnosis weren't taken. Such diagnoses as “bruise of soft tissues of the head” and “compression of a head” that haven't been confirmed by any clinical data and in forensic assessment wasn't considered under “Rules of forensic determination of the severity of injuries”, approved by the Order № 6 of Ministry of Health of Ukraine, 17.01.1995. The above data indicate, that at diagnosis “TBI” clinicians don't adhere to the standards prescribed in clinical protocols of providing medical care patients with different forms of TBI. Because of that reasons during examination forensics experts have difficulty, because the main role in forensic assessment plays a regular medical records and justified a series of clinical medico-diagnostic measures, especially in cases when after injury much time have passed, and clinical displays of TBI may disappear. Thus, in our view, and in such cases we can talk

about the medico-diagnostic defects, that should be specified in conclusions of forensic examination.

Introduction. Among all injury head injury is a leader. In Ukraine and some post-Soviet countries head injuries as concussions, bruises, diffuse axonal brain damage and intracerebral hematomas called a cranio-cerebral trauma. They also include fractures of base and calvaria. At the same time, in countries of Europe and America there is a term “traumatic brain injury” (TBI), which indicates only a brain injury, which is more correct, because the name “cranio-cerebral trauma” actually combines damage to bones of the skull and intracranial contents. There are different systems for classifying traumatic brain injury. Systems include classifying traumatic brain injury by severity, which is generally based on clinical indexes at the time of presentation. TBI can be classified by pathoanatomic type i.e. type of injury such as diffuse axonal injury, haematoma and haemorrhages. [1-3]. In Ukraine, according to official data, from this disease dies more than 11 thousand people, of whom 55% die in the prehospital phase and 41% - in the hospital, which exceeds the level of hospital mortality in developed countries more than 1.5 times [4]. Because TBI is one of the leading places in the structure of total injuries, it's one of the most important aspects of forensic investigations. Each country has its own approach to forensics in cases of TBI, particularly in the United States a large role in the assessment of TBI is given to forensic neuropsychiatrists [5]. In Ukraine the forensic examination held involving neurologists or neurosurgeons. In cases of installation of defects of medical care, including in cases of TBI, according to current legislation of Ukraine a commission forensic examination regarding “Doctoring” must be appointed [6, 7]. Such examination carried out to determine the specific defects providing medical care and address a number of issues related to the violation of the medical staff of professional duty. But sometimes during the forensic examination into the death installation or severity of injuries some doctors diagnoses are unfounded. Most of them are just TBI, including concussion. Thus, in such cases, we can talk about the medico-diagnostic defects (hypo- and hyperdiagnosis).

The aim of the research was to study the defects, allowed by doctors in cases of TBI, according to forensic examination of a bureau forensics Ukraine to prevent errors forensic experts in assessing TBI.

Materials and methods. Research materials were 1304 forensic examination of the departments of forensic examination of victims, defendants and others in one of the regional bureau of forensic medical examination Ukraine for 2008-2012.

The data subjected to statistical analysis by standard methods of descriptive statistics using BIOSTAT. Statistical analysis included the calculation of primary statistical parameters (mean and standard error (M)).

RESULTS AND DISCUSSION

In the statistical analysis of examinations, conducted in the department of forensic examination of victims in Regional Bureau for the 2008-2012, it was found that cases of TBI met at 37.94% of all examinations (1304 of 3437 total number). The number of examinations in cases of TBI each year increased from $25,9 \pm 2,05\%$ in 2008 to $37,38 \pm 2,05\%$ in 2012 (Fig.1).

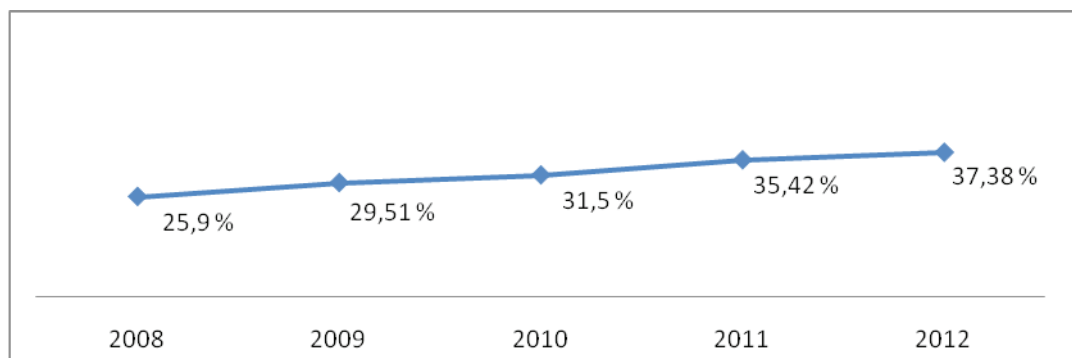


Fig. 1. Dynamics of examinations in TBI cases from 2008 to 2012 yy according to forensic examination department of victims, defendants and others.

Analyzing the examination, it was found that in medical records for forensics in many cases doctors established diagnosis “TBI” incorrectly, especially in cases of clinically-mild traumatic brain injury - concussion of a brain and bruises of a brain of mild degree, which amounted to 81.35% and 13.98%, respectively (Fig.2). During the forensic examination in all these cases the establishment of the diagnosis weren’t taken.

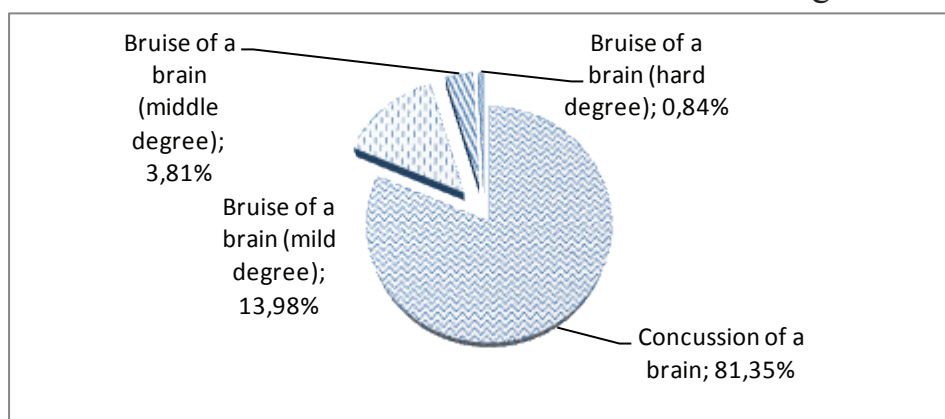


Fig. 2. Distribution of unreasonably diagnosed different form sof TBI according to the forensic examination department of victims, defendants and others.

Most of the unfulfilled medico-diagnostic and therapeutic measures concerned concussion of a brain. Thus, in the diagnosis of “concussion” in $93,3 \pm 1,3\%$ not conducted CT or MRI of the brain, in $91,2 \pm 1,5\%$ the medico-diagnostic-therapeutic lumbar puncture wasn’t done, in $87,4 \pm 1,9\%$ - craniography of a skull, $60 \pm 1,85\%$ - reo encephalographic research vessels of the brain, $43 \pm 1,84\%$ - electroencephalographic study. About the quality of patient examination It’s striking that the neurological status of the majority of patients ($67,7 \pm 1,93\%$) wasn’t described in full, with complete neglect of neurological symptoms, peculiar to a particular form of TBI. Complicating forensic assessment also the fact that in some cases ($24,3 \pm 2,25\%$) neurologists diagnosed “concussion” only on the basis of subjective patient complaints (headache, dizziness,

nausea, etc.) and anamnesis (head injury, according to the patient's words). However, no patient was examined neurosurgeons, ophthalmologists and otorhinolaryngologist, what's necessary in cases of head injury. In some cases the diagnosis of "concussion" was established by traumatologists, surgeons, etc., that non-core specialty physicians.

As for the more severe TBI as the bruise of a brain, the defects, that were found in the analysis of medical records in the forensic examination, were similar to what occurred with concussion. However, it must be said, that along with incomplete clinical symptoms, that would confirm bruise of a brain, that was observed in the majority of cases ($67,3 \pm 1,12\%$), were cases of the total absence of symptoms ($6,8 \pm 1,05\%$). In $15,4 \pm 1,72\%$ of cases patients haven't performed CT or MRI of the brain. Usually that was in cases of bruises of a brain of mild degree. Although, according to the special medical literature, mild bruises of a brain sometimes couldn't be visualized by CT or MRI in the early stages (e.g. "oedematic form"), but such research is required in the diagnosis of "brain bruise", that indicated in the clinical protocols of medical care to patients with brain contusion various degrees, and also in concussion of a brain (Clinical Protocol to provide medical care to patients with brain concussion).

In the medical records also met such diagnoses as "Bruise of soft tissues of the head" and "compression of a head" that haven't been confirmed by any clinical data and in forensic assessment wasn't considered under "Rules of forensic determination of the severity of injuries", approved by the Order № 6 of Ministry of Health of Ukraine, 17.01.1995.

About intracerebral hematomas, such diagnosis was observed in 24 cases, accounting for only 0.7% of the total number of examinations conducted in the department, and 1.84% for examination concerning TBI. However, among all victims in most cases was observed subarachnoid hemorrhage (18 cases, accounting for 75% of all hematomas). Incorrectly diagnosed concerned only subarachnoid hemorrhage. Thus, the diagnosis "subarachnoid hemorrhage" wasn't confirmed in carrying out forensic examinations in almost half of cases ($44,44 \pm 0,93\%$), in particular, such patients have not performed CT or MRI of the brain, in lumbar puncture wasn't received blood or lumbar puncture wasn't performed at all. It should be noted that the diagnosis "subarachnoid hemorrhage" was confirmed in all cases where he accompanied confirmed bruise of a brain. In cases where doctors set unreasonably bruise of a brain, subarachnoid hemorrhage was also not confirmed.

In the analysis of forensic examinations in cases of TBI fracture of foundation and calvaria were found in 32 cases, accounting for 2.45% of the total number of examinations with TBI. However, in 12 cases ($37,5 \pm 2,34\%$) diagnosis wasn't confirmed radiographically. It should also be noted that the definition of fracture formation of flat bones of a skull - not easy task for a forensic expert, because in adults full healing of fractures of flat bones of the skull, usually does not occur, but is determined by the partial fusion of both linear and splinter fractures. So it's necessary to carefully examine the medical injury to rule out fractures of the skull of the victim in the past. Due to this during forensic examinations we are faced with the fact that in 4 cases skull

fractures doctors in the hospital were wrongly classified as fresh. In analyzing the same medical records of patients who were invited in the investigation, it was found that fractures in these victims were formed before the events referred by victims.

In Ukraine in neurosurgical practice is generally accepted diagnosis “brain bruise” in the presence of depressed fracture of the skull even without CT and MRI. Here is an example. In medical documentation given by neurosurgeons was diagnosed “Contused wound parietal area of the head. Depressed fracture of the left parietal bone, bruised brain moderate severity. “In conducting the forensic examination was found that the diagnosis “left parietal bone fracture” wasn’t confirmed radiographically, including the additional X-ray study of the head using special positions and by CT and MRI. Thus, the deformation of the outer bone plate in the left parietal area was mistaken regarded by hospital doctors as a depressed fracture of the skull. Bruise of a brain, according to CT and MRI, was also absent. Thus, the victim took place only contused wound of parietal area.

CONCLUSIONS:

1. In the statistical analysis of examinations, conducted in the department of forensic examination of victims defendants and others in Regional Bureau for the 2008-2012, it was found that cases of TBI met at 37.94% of all examinations(1304 of 3437 total number). The number of examinations in cases of TBI each year increased from $25,9 \pm 2,05\%$ in 2008 to $37,38 \pm 2,05\%$ in 2012.

2. Analyzing the examination, it was found that in medical records for forensics in many cases doctors established diagnosis “TBI” incorrectly, especially in cases of clinically-mild traumatic brain injury - concussion of a brain and mild brain bruises, which amounted to 81.35% and 13.98%, respectively. During the forensic examination in all these cases the establishment of the diagnosis weren’t taken.

3. Such diagnoses as “bruise of soft tissues of the head” and “compression of a head” that haven’t been confirmed by any clinical data and in forensic assessment wasn’t considered under “Rules of forensic determination of the severity of injuries “, approved by the Order № 6 of Ministry of Health of Ukraine, 17.01.1995.

4. The above data indicate, that at diagnosis “TBI” clinicians don’t adhere to the standards prescribed in clinical protocols of providing medical care patients with different forms of TBI. Because of that reasons during examination forensics experts have difficulty, because the main role in forensic assessment plays a regular medical records and justified a series of clinical medico-diagnostic measures, especially in cases when after injury much time have passed, and clinical displays of TBI may disappear. Thus, in our view, and in such cases we can talk about the medico-diagnostic defects, that should be specified in conclusions of forensic examination.

Literature

1. **Saatman K**, Duhaime A, Bullock R, Maas A, Valadka A. Classification of Traumatic Brain Injury for Targeted Therapies/Journal of Neurotrauma.–2008. – Vol. 25(7). – p. 719-38.
2. **International** statistical classification of diseases and related health problems

(10th ed.)/World Health Organization.– Geneva, Switzerland.– 1992

3. **Malec JF**, Brown AW, Leibson CL, Flaada JT, Mandrekar JN, Diehl NN, Perkins PK. The Mayo Classification System for Traumatic Brain Injury Severity/ Journal of Neurotrauma.–2007.–Vol. 24(9). –p.17-24.
4. **Gregory Murrey Ph.D.**, Donald Starzinski Ph.D. M.D. The Forensic Evaluation of Traumatic Brain Injury/A Handbook for Clinicians and Attorneys, Second Edition Hardcover.– November 8, 2007.
5. **Law of Ukraine** “On legal expertise” [electronic resource] / Supreme Council of Ukraine (BD) - К., 2004, - № 28- st.232 - Access: <http://zakon.rada.gov.ua>- name of the screen.
6. **Order № 6** of Ministry of Health of Ukraine, 17.01.1995[electronic resource] / Ministry of Health of Ukraine - Kyiv, 1995. -№ 6. - Access : <http://zakon1.rada.gov.ua>- title screen.

СУДОВО-МЕДИЧНА ОЦІНКА НЕЛЕТАЛЬНОЇ ЧЕРЕПНО-МОЗКОВОЇ ТРАВМИ У ПОСТРАЖДАЛИХ, ЯКІ ЛІКУВАЛИСЯ У МЕДИЧНИХ ЗАКЛАДАХ

Плетенецька А.О.

Резюме. Враховуючи високу поширеність черепно-мозкової травми в судово-медичній практиці, метою дослідження було вивчення дефектів, що допускаються лікарями у випадках ЧМТ, за даними судово-медичних експертиз відділу судово-медичної експертизи потерпілих, обвинувачених та інших осіб одного з обласних бюро судово-медичної експертизи Україна по 2008-2012 рр., для запобігання помилок судово-медичних експертів в оцінці ЧМТ. У статті представлені дані судово-медичних експертиз потерпілих в подібних випадках, описані основні дефекти лікарів неврологів, які допускаються при діагностиці ЧМТ, оскільки провідну роль у судово-медичній оцінці грає правильно оформлена медична документація і обгрунтоване проведення низки клініко-діагностичних заходів, що може допомогти судово-медичну експертам у правильній оцінці черепно- мозкової травми.

Ключові слова: судово-медична експертиза, черепно-мозкова травма, лікувально-діагностичні дефекти.